

PennHIP Report

Referring Veterinarian: Dr Timothy Lassett

Email: northbayanimal@tampabayvets.net

Clinic Name: North Bay Animal and Bird Hospital

Clinic Address: 9801 West Hillsborough Avenue

Tampa, FL 33615

Phone:

Fax:

Patient Information

Client: Kirkpatrick, Jennipher

Patient Name: Maggie Mae

Reg. Name: Maggie Mae Mcfly

PennHIP Num: 202918

Species: Canine

Date of Birth: 27 Feb 2021

Sex: Female

Date of Study: 03 Jun 2024

Date of Report: 06 Jun 2024

Tattoo Num:

Patient ID: 3616

Registration Num: SS22530303

Microchip Num:

Breed: GOLDEN RETRIEVER

Age: 40 months

Weight: 65.5 lbs/29.7 kgs

Date Submitted: 04 Jun 2024

Findings

Distraction Index (DI): Right DI = 0.38, Left DI = 0.28.

Osteoarthritis (OA): No radiographic evidence of OA for either hip.

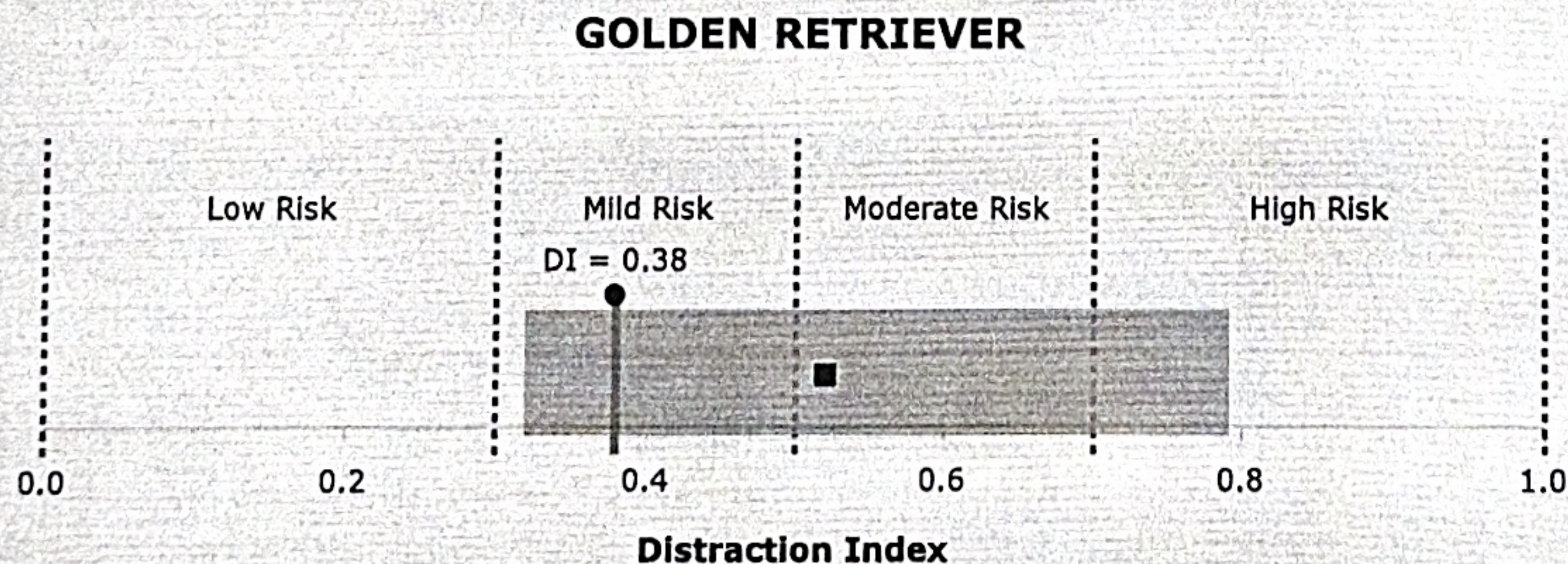
Cavitation/Other Findings: No cavitation present.

Interpretation

Distraction Index (DI): The laxity ranking is based on the hip with the greater laxity (larger DI). In this case the DI used is 0.38.

OA Risk Category: The DI is between 0.31 and 0.49. This patient is at mild risk for hip OA.

Distraction Index Chart:



BREED STATISTICS: This interpretation is based on a cross-section of 27049 canine patients of the GOLDEN RETRIEVER breed in the AIS PennHIP database. The gray strip represents the central 90% range of DIs (0.32 - 0.79) for the breed. The breed average DI is 0.52 (solid square). The patient DI is the solid circle (0.38).